

# SENSITIVITY AND SPECIFICITY OF INSM1 IN DIFFERENTIATING NEUROENDOCRINE CARCINOMA OF THE HEAD AND NECK FROM NONKERATINIZING NASOPHARYNGEAL CARCINOMA AND P16-POSITIVE OROPHARYNGEAL SQUAMOUS CELL CARCINOMA

*Phatsorn Amattirat<sup>\*</sup>, Thirayost Nimmanon<sup>\*\*</sup>, Parsinee Julimasart<sup>\*</sup>, Kulachet Wiwatwarayos<sup>\*,\*\*</sup>*

**\*Institute of Pathology, Ministry of Public Health, Bangkok, Thailand**

**\*\*Department of Pathology, Phramongkutklao College of Medicine, Bangkok, Thailand**

---

## Abstract

**Background:** Neuroendocrine carcinomas (NECs) rarely arise in the head and neck region. Their diagnosis presents challenges due to morphological overlap with other entities, particularly nonkeratinizing nasopharyngeal carcinomas (NK-NPC) and p16-positive oropharyngeal squamous cell carcinomas (p16-positive OPSCC), both of which are prevalent in Thailand. Insulinoma-associated protein 1 (INSM1) is a relatively new marker that has demonstrated favorable sensitivity and specificity in various organs. However, despite its promising potential, there is a paucity of studies investigating its utility in the head and neck region compared to other anatomical sites, especially in Thailand.

**Objectives:** This study aimed to evaluate the diagnostic performance of INSM1 in distinguishing NECs of the head and neck region from NK-NPC and p16-positive OPSCC by comparing its sensitivity and specificity with classic neuroendocrine markers, chromogranin A (CGA) and synaptophysin (SYN).

**Methods:** This retrospective cohort study analyzed 14 samples of NEC and 109 samples, comprising 93 NK-NPC and 16 p16-positive OPSCC cases. Immunohistochemical (IHC) staining for INSM1, CGA, and SYN was performed on all cases. Receiver Operating Characteristic (ROC) curve analysis was utilized to determine the optimal cutoff point for INSM1 positivity, maximizing both sensitivity and specificity.

**Results:** INSM1 demonstrated an overall sensitivity of 92.9% for head and neck NECs, comparable to SYN (100.0%,  $p = 0.001$ ) but significantly higher than CGA (78.6%,  $p = 0.006$ ). All three markers (INSM1, CGA, and SYN) achieved 100.0% specificity in differentiating NECs from NK-NPC and p16-positive OPSCC. ROC analysis determined an optimal cutoff of 75% tumor cell positivity for INSM1, with a Youden's index of 0.93 and an Area Under the Curve (AUC) of 0.952, indicating excellent diagnostic accuracy. Notably, one case of Epstein-Barr virus (EBV)-positive NK-NPC exhibited INSM1 positivity in 40% of tumor cells with moderate to strong intensity.

**Conclusion:** INSM1 exhibits good sensitivity and excellent specificity for head and neck NECs, comparable to or surpassing those of CGA and SYN, respectively. While its high specificity is valuable, the observed positivity in a subset of NK-NPC cases, even below the optimal cutoff, suggests that INSM1 should not be used as a standalone diagnostic marker for NECs. Caution is advised when interpreting INSM1 staining in less than 75% of tumor cells, as this may reduce the reliability of a positive finding. A comprehensive panel that includes classic neuroendocrine markers and, where appropriate, EBER in situ hybridization remains crucial for accurate diagnosis.

**Keywords:** INSM1, neuroendocrine carcinoma, head and neck, specificity, sensitivity, interpretation

J Southeast Asian Med Res 2025; 9: e0243

<https://doi.org/10.55374/jseamed.v9.243>

Correspondence to:

Amattirat P, Institute of Pathology, Department of Medical Services, Ministry of Public Health, Phayathai Road, Thung-Phayathai, Ratchathewi, Bangkok 10400, Thailand

Email: pusphatsorn@gmail.com

Received: 9 May 2025

Revised: 3 September 2025

Accepted: 17 December 2025

## Introduction

Neuroendocrine carcinomas (NECs) are uncommon malignancies of the head and neck region. Their undifferentiated morphology often presents a significant diagnostic challenge, as they can closely resemble other common head and neck tumors, particularly nonkeratinizing nasopharyngeal carcinoma (NK-NPC) and p16-positive oropharyngeal squamous cell carcinoma (p16-positive OPSCC).<sup>(1,2)</sup> Given these morphological similarities, immunohistochemical (IHC) studies are essential for confirming the diagnosis and guiding appropriate patient management. Further complicating diagnosis, reports describe Epstein-Barr Virus (EBV)-associated large cell neuroendocrine carcinoma (LCNEC) and small cell neuroendocrine carcinoma (SCNEC) in the nasopharynx.<sup>(3,4)</sup> Additionally, NK-NPCs can exhibit weak or moderate pan-cytokeratin expression, and squamous markers like p63 and p40 may show only focal or negative staining, deviating from their expected strong and diffuse positivity in typical squamous cell carcinomas.<sup>(5)</sup> Furthermore, SCNEC can be p16 IHC positive, potentially leading to a misdiagnosis as p16-positive OPSCC.<sup>(6)</sup> Chromogranin A (CGA) and Synaptophysin (SYN) are the traditional IHC markers used to determine neuroendocrine differentiation. Their reported sensitivities range from 77.3% for CGA to 92.3% for SYN, and specificities are around 92.4% for CGA and 93.5% for SYN.<sup>(7,8,9)</sup> However, their utility can be limited by variable expression and nonspecific staining in some non-neuroendocrine tumors. Recently, insulinoma-associated protein 1 (INSM1), an emerging neuroendocrine markers, has been

investigated for its diagnostic utility across various organs, including the head and neck, predominantly in Western countries. INSM1 exhibits high sensitivity (up to 99.0%) and specificity (up to 97.6%) in the detection of neuroendocrine tumors. Its nuclear staining pattern enhances its value, making it easier to interpret in pathological practice. Several studies suggest that INSM1 may serve as a standalone marker for NECs.<sup>(10-17)</sup> Despite its promising potential, there are no studies investigating INSM1's performance in differentiating NECs from NK-NPC and p16-positive OPSCC, especially within the Thai population. Previous research on head and neck squamous cell carcinomas has reported only one OPSCC case showing synaptophysin positivity, with no expression of INSM1 or CGA. For NK-NPC, no prior studies have reported INSM1 expression, nor have they extensively examined SYN and CGA expression in this specific context.<sup>(18)</sup> Interestingly, NK-NPC has been linked to differential expression of several genes (ATP12A, LAMB1, RAD51AP1, CXCL11, INSM1, PTGS2, and SAA1), including INSM1, which has been shown to modulate NPC response to radiation via a cyclin D1-dependent DNA repair pathway, highlighting its potential molecular significance in NPC treatment.<sup>(19)</sup> Given these diagnostic challenges and the lack of comprehensive local data, this study aims to assess the diagnostic performance of INSM1 in distinguishing head and neck NECs from their common histologic mimics, specifically NK-NPC and p16-positive OPSCC, by comparing its sensitivity and specificity with those of CGA and SYN.

## Methods

### *Ethical statements*

This retrospective cohort study was approved by the Institutional Review Board of the Institute of Pathology (number: IOP-KMR66-004). The board exempted the requirement for informed consent documentation due to the retrospective nature of the analysis. This approval ensures that our research adheres to the relevant ethical guidelines.

### *Case selection*

Cases of NK-NPC (regardless of EBV status), p16-positive OPSCC, SCNEC, and LCNEC of the head and neck region were retrieved from formalin-fixed, paraffin-embedded tissue blocks archived at the Institute of Pathology, Ministry of Public Health, Bangkok, Thailand. These specimens, including punch biopsies, needle biopsies, excisions, and surgical resections, were collected between 2015 and 2024. Due to the rarity of neuroendocrine carcinoma, all 14 available NEC cases were included, consisting of 10 SCNEC and 4 LCNEC cases. For the non-NEC group, a sample size was calculated using the formula for estimating Finite Population Proportion (Wayne WD, 1995) to ensure statistical reliability, given the large number of NK-NPC and p16-positive OPSCC cases.<sup>(20)</sup> The non-NEC group included 93 cases of NK-NPC and 16 cases of p16-positive OPSCC, totaling 109 non-NEC cases. All selected cases were subjected to IHC staining for INSM1, SYN, and CGA to ensure uniform evaluation across the cohort.

### *Evaluating the percentage of tumor cells and intensity*

The percentage of tumor cells showing positive staining was recorded from 10 consecutive high-power fields (HPFs, 400x magnification) under a light microscope (Olympus BX53, Japan, with a field diameter of 0.55 mm), starting from the field with the highest tumor density. The staining was then categorized into percentages of tumor cell positivity (0%, 1%, 5%, 10%, 15%, 20%, 25%, 30%, ... 100%). Staining intensity was graded as 0 (negative), 1+ (weak), 2+ (moderate), or 3+ (strong). All diagnoses and

stained slides were reviewed under the microscope by a resident in anatomical pathology and subsequently confirmed by a consultant pathologist. The findings were meticulously documented in a standardized research record form.

### *INSM1, CGA, and SYN immunohistochemical studies*

Specimens were stained with INSM1 (MRQ-70, Cell Marque) rabbit monoclonal antibody. If SYN or CGA staining had not been previously performed, SYN (MRQ-40, Cell Marque) rabbit monoclonal antibody and CGA (LK2H10, Cell Marque) mouse monoclonal antibody were also applied to cases where prior staining had not been performed. The dilutions were: INSM1 (1:100), SYN (1:50), and CGA (1:500). All 14 NEC cases (10 SCNEC and 4 LCNEC), 93 cases of NK-NPC, and 16 cases of p16-positive OPSCC were stained with SYN, CGA, and INSM1. Tissue sections, 3 micrometers thick, underwent heat-induced antigen retrieval in 10 mM citrate buffer at 100°C for 42 minutes using the LEICA BOND-MAX system. External quality control for IHC staining included the use of positive and negative tissue controls, as per the laboratory's standard procedures. Pancreatic islet cells served as a positive control to verify reagent performance and staining accuracy, while negative controls utilized either the same tissue without primary antibody or reagent-only controls to detect nonspecific staining. All controls were processed identically to test samples and reviewed by a pathologist under the microscope before interpretation to ensure the validity and reliability of the results.

### *Statistical analysis*

This study utilized proprietary software, IBM SPSS Statistics (version 26, IBM Corp.), and the R programming language (version 4.2, R Foundation for Statistical Computing). The Area Under the Curve (AUC) was interpreted as follows:  $\geq 0.90$  (Excellent),  $0.80 < 0.90$  (Good),  $0.70 < 0.80$  (Fair),  $0.60 < 0.70$  (Poor), and  $0.50 < 0.60$  (Fail). For a test to demonstrate meaningful performance, the AUC must exceed 0.50; generally, an AUC of 0.80 or higher is considered accept-

able. The McNemar's  $\chi^2$  test was used to compare the sensitivity and specificity of INSM1 with those of SYN and CGA, which was appropriate for comparing diagnostic tests on the same subjects.

## Results

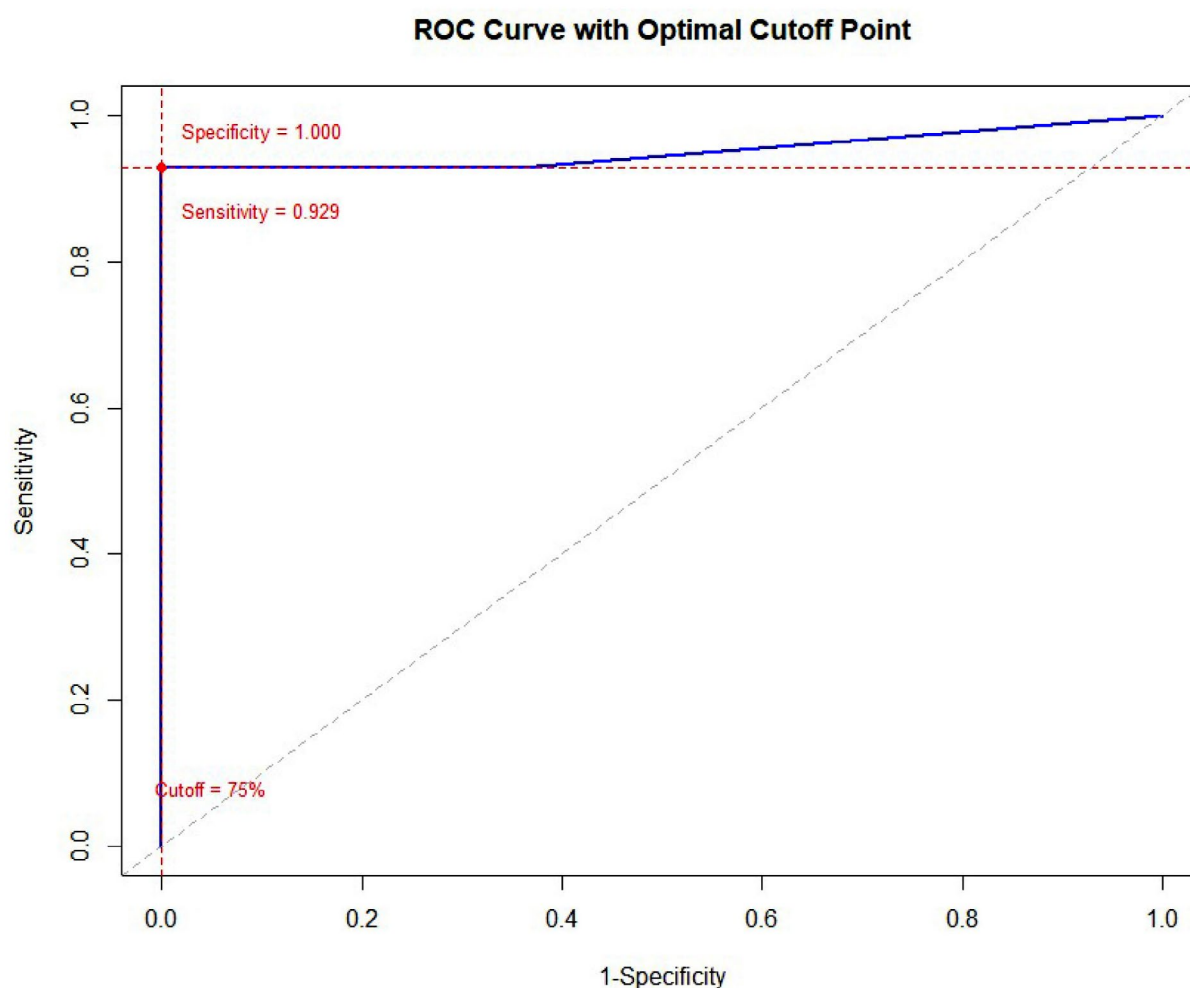
### *Receiver Operating Characteristic (ROC) curve analysis and optimal cutoff determination*

To determine the optimal cutoff for INSM1 positivity, Receiver Operating Characteristic (ROC) curve analysis was performed. Cutoff points were identified to maximize both sensitivity and specificity, representing the optimal classifier. As illustrated in **Figure 1** and **Table 1**, the optimal cutoff of 75% tumor cells was determined using the ROC curve based on INSM1 positivity, with the Maximum Youden's Index (0.93) serving as the chosen cutoff. This analysis yielded an Area Under the Curve (AUC) of 0.952, indicating excellent accuracy in distinguishing NECs from NK-NPC and p16-positive OPSCC cases. These tumors exhibit similar, overlapping morphologies, making them challenging to differentiate in routine practice. Therefore, in our opinion, calculating the overall AUC would be more appropriate in this context. Youden's Index (J), also known as Youden's J statistics, is a statistical metric that measures the overall performance of a diagnostic test. The optimal cutoff point for a test is the value that maximizes Youden's Index, which was calculated as sensitivity + specificity - 1. This point represents the optimal balance between accurately identifying NECs (high sensitivity) and accurately excluding non-NECs (high specificity). Consequently, when INSM1 is positive in more than 75% of the total tumor area, NEC is strongly considered for diagnosis. Conversely, positivity below this threshold (75%) is observed in NK-NPC and p16-positive OPSCC, necessitating careful interpretation. The 75% cutoff was chosen because it

provides the best balance of sensitivity and specificity, minimizing classification errors and aligning with the study's clinical priorities.

### *Comparison of sensitivity and specificity*

A two-step sequential process was used to determine the sensitivity and specificity of all markers. First, ROC curve analysis identified the optimal cutoff point for INSM1 expression, providing a threshold with the best balance of sensitivity and specificity. Second, this cutoff point was applied to construct a 2x2 contingency table, from which the final sensitivity and specificity values for INSM1 were directly calculated. For CGA and SYN, their sensitivity and specificity were determined directly from 2x2 contingency tables based on any discernible positive staining, aligning with established positivity criteria in the literature. As shown in **Tables 2 and 3**, INSM1 had an overall sensitivity of 92.9%; this was significantly higher than CGA (78.6%,  $p = 0.006$ ) but lower than SYN (100.0%,  $p = 0.001$ ). There was a statistically significant difference in sensitivity between INSM1, CGA, and SYN in the sample of head and neck NECs. In terms of specificity, INSM1 demonstrated 100.0%, comparable to CGA (100.0%) and SYN (100.0%). As all specificities were 100.0% for the non-NEC group, there was no statistically significant difference in specificity among INSM1, CGA, and SYN (all  $p = 1.000$ ). All p16-positive OPSCC cases were negative for INSM1, SYN, and CGA. Interestingly, one EBV-positive NK-NPC case showed INSM1 positivity in approximately 40% of tumor cells, with moderate to strong intensity (2+ to 3+). This unexpected finding is illustrated in **Figure 2**, where tumor cell positivity was assessed across 10 consecutive high-power fields (HPFs) from the area of highest tumor density and recorded in predefined increments. This particular NK-NPC case, however, was entirely negative for SYN and CGA.



**Figure 1.** Receiver Operating Characteristic (ROC) curve for INSM1 differentiating NECs from NK-NPC and p16-positive OPSCC. The plot illustrates the trade-off between sensitivity and specificity for various INSM1 positivity cutoffs. The area under the curve (AUC) is shown, with the optimal cutoff point 75% (red dot) indicating the best balance between sensitivity and specificity.

**Table 1.** Sensitivity and specificity at various INSM1 percentage cutoffs.

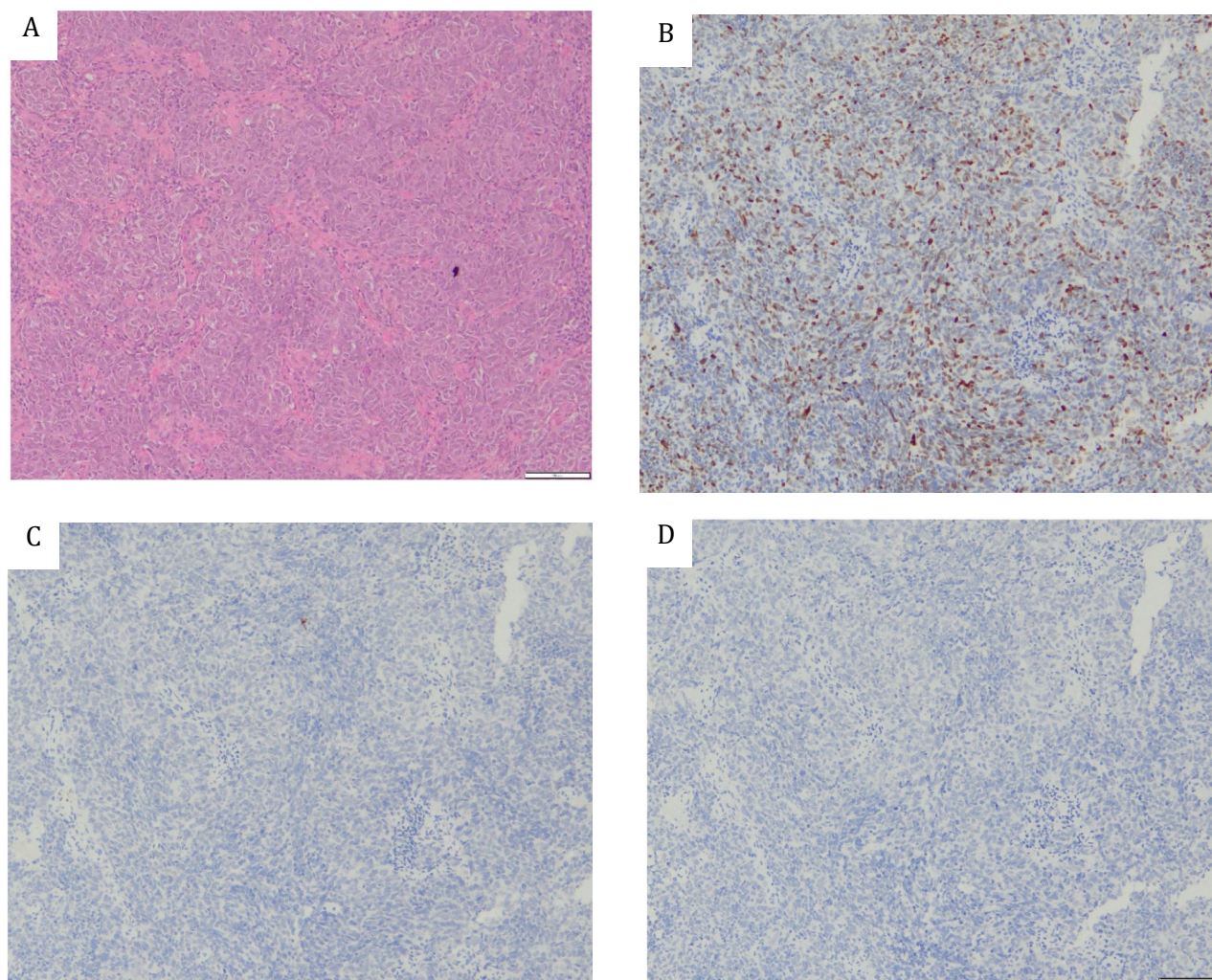
sINSM1 percentage	Sensitivity	Specificity
0	100.0%	0.0%
1	92.9%	64.2%
5	92.9%	69.7%
10	92.9%	93.6%
20	92.9%	96.3%
30	92.9%	98.2%
40	92.9%	99.1%
<b>75</b>	<b>92.9%</b>	<b>100.0%</b>
80	71.4%	100.0%
90	64.3%	100.0%
100	57.1%	100.0%



**Table 2.** Expression of INSM1, SYN, and CGA in SCNEC, LCNEC, NK-NPC, and p16-positive OSCC

Diagnosis	(n/N [%])					
	INSM1		SYN		CGA	
	Positive <sup>A</sup>		Positive	Negative	Positive	Negative
<b>NECs</b>	<b>13/14 (92.9)</b>	<b>1/14 (7.1)</b>	<b>14/14(100)</b>	<b>0/14 (0)</b>	<b>11/14(78.6)</b>	<b>3/14 (21.4)</b>
SCNEC	10/10 (100)	0/10 (0)	10/10(100)	0/10 (0)	9/10 (90.0)	1/10 (10.0)
LCNEC	3/4 (75.0)	1/4 (25.0)	4/4 (100)	0/4 (0)	2/4 (50.0)	2/4(50.0)
<b>Non-NECs</b>	<b>0/109 (0)</b>	<b>109/109 (100)</b>	<b>0/109 (0)</b>	<b>109/109 (100)</b>	<b>0/109 (0)</b>	<b>109/109 (100)</b>
p16-positive OPSCC	0/16 (0)	16/16 (100)	0/16 (0)	16/16 (100)	0/16 (0)	16/16 (100)
NK-NPC	0/93 (0)	93/93 (100)	0/93 (0)	93/93 (100)	0/93 (0)	93/93 (100)

<sup>A</sup>Cut point: 75% of tumor cells positive

**Figure 2.** Representative images of an NK-NPC case showing INSM1 positivity. (A) Hematoxylin and Eosin (H&E) stain demonstrating the characteristic morphology of NK-NPC. (B) INSM1 IHC stain revealing 40% tumor cell positivity with moderate to strong intensity (2+-3+). In contrast, (C) SYN and (D) CGA IHC stains show a complete lack of staining.

### Summary of diagnostic performance

To provide a clear overview of the diagnostic capabilities of each marker, the overall sensitivity and specificity for INSM1, SYN, and CGA in differentiating head and neck NECs from NK-SCC and p16-positive OPSCC are summarized in **Table 3**.

### Discussion

This study evaluated INSM1's ability to distinguish head and neck NECs from similar tumors by comparing its sensitivity and specificity with those of CGA and SYN. Our findings, summarized in Table 3, indicate that SYN exhibited the highest sensitivity at 100%, followed by INSM1 at 92.9%, and CGA at 78.6%. These results differ somewhat from previous research, which reported INSM1 having the highest sensitivity at 99.0%, followed by SYN at 92.3%, and CGA at 77.3%. These variations could be attributed to differences in patient populations, specific antibody clones used, or differing interpretation criteria across studies. Regarding specificity, all three markers demonstrated 100% specificity in this study, in contrast to earlier findings, in which INSM1 exhibited the highest sensitivity at 97.6%, SYN at 93.5%, and CGA at 92.4%.<sup>(7,8,9)</sup> The consistently high specificity observed in our study for all markers may reflect the specific selection of non-NEC mimics (NK-NPC and p16-positive OPSCC), which are generally not expected to express neuroendocrine markers.

Although INSM1 demonstrated 100% specificity across all non-NEC cases, with all p16-positive OPSCC cases testing negative, there was one notable exception: an EBV-positive NK-NPC case showed 40% tumor cell positivity. This finding suggests that INSM1 could be a

useful adjunct marker for excluding nasopharyngeal NEC when it is strongly positive. To date, no studies have reported INSM1 expression in EBV-positive NPC; however, some research has identified INSM1 as a gene expressed via the cyclin D1-dependent DNA repair pathway, which may provide a molecular basis for this unexpected staining.<sup>(19)</sup> Furthermore, the absence of INSM1 expressions in all p16-positive OPSCC cases was noteworthy. This finding aligns with previous research reporting INSM1 negativity in oral squamous cell carcinoma, suggesting that INSM1 could serve as a helpful adjunct in excluding NECs in the oropharynx.<sup>(21)</sup>

The unexpected INSM1 positivity in a subset of NK-NPC cases, reaching up to 40% of tumor cells, presented a significant diagnostic challenge, particularly in resource-limited settings where EBER in situ hybridization, the gold standard for NK-NPC diagnosis, may not be readily available. Given that NK-NPC can occasionally exhibit diagnostic ambiguity due to weak or absent expression of conventional squamous markers,<sup>(22)</sup> pathologists might reflexively employ additional neuroendocrine markers. The observed INSM1 positivity in NK-NPC underscored the risk of misclassification, potentially leading to inappropriate patient management. Therefore, a combined assessment of CGA and SYN, alongside EBER in situ hybridization, is the most reliable approach for accurately differentiating NEC from NK-NPC in the head and neck region. (23, 24) The relatively small sample size of NEC cases (n=14), inherent to the rarity of this entity in the head and neck region, represents a limitation of this study. This retrospective, single-center design also poses potential limitations regarding selection bias and the generalizabil-

**Table 3.** Sensitivity and specificity of INSM1, SYN, and CGA for head and neck NECs.

Marker	Sensitivity (%)	Specificity (%)
INSM1 <sup>A</sup>	92.9	100
Synaptophysin (SYN)	100	100
Chromogranin A (CGA)	78.6	100

A Cutoff point: 75% of tumor cells positive

ity of findings to broader populations. Future research with larger, multi-institutional cohorts is warranted to further validate these findings and provide greater statistical power, and to explore potential correlations between INSM1 expression and clinical outcomes.

## Conclusion

This study provides valuable insight into the diagnostic utility of INSM1 in head and neck NECs, offering a practical IHC marker with high sensitivity and specificity. Its evaluation alongside established markers and determination of an optimal cutoff point enhances diagnostic accuracy and may improve clinical decision-making. These findings could contribute to more precise tumor classification and better patient management in this challenging anatomical region.

While INSM1 demonstrates good sensitivity, comparable to traditional neuroendocrine markers, for head and neck NECs, its utility as a standalone marker to definitively confirm or exclude NEC and to reliably differentiate it from NK-NPC is limited by observed positivity in a subset of NK-NPC cases. Caution is advised when interpreting INSM1 positivity, particularly when staining involves less than 75% of tumor cells. In resource-limited settings, relying solely on INSM1 may lead to diagnostic pitfalls. Therefore, a comprehensive diagnostic approach integrating conventional neuroendocrine markers (CGA and SYN) remains crucial for accurate differentiation. The rarity of head and neck NECs poses a challenge for research, and future studies with larger cohorts are needed to refine our understanding and optimize diagnostic strategies for these challenging tumors.

## Acknowledgments

This research was funded by the Institute of Pathology Foundation (grant number 7/2567). We would like to express our gratitude to the Institute of Pathology Foundation for their financial support, which made this research possible.

## Conflict of interest

The authors declare that they have no conflict of interest.

## Availability of data and materials

Due to patient confidentiality and regulations of the Institute of Pathology, Ministry of Public Health, Thailand, the data is not publicly available. However, researchers may request access from the corresponding author, subject to approval by the Institute of Pathology's ethics committee.

## References

1. Ohmoto A, Sato Y, Asaka R, Fukuda N, Wang X, Urasaki T, et al. Clinicopathological and genomic features in patients with head and neck neuroendocrine carcinoma. *Mod Pathol* 2021; 34: 1979-89.
2. Alos L, Hakim S, Larque AB, Rodriguez-Carunchio L, Caballero M, et al. p16 overexpression in high-grade neuroendocrine carcinomas of the head and neck: potential diagnostic pitfall with HPV-related carcinomas. *Virchows Arch* 2016; 469: 277-84.
3. Su Z, Yan H, Zou G. EBV positive large cell and small cell neuroendocrine carcinoma of the nasopharynx: a case report and review of the literature. *Oncol Lett* 2022; 24: 1.
4. Chen Y, Zhou N, Huang C, He X, Wang X, Tang H, et al. EBV-positive small cell neuroendocrine carcinoma of nasopharynx as a probably unique subtype of neuroendocrine carcinoma: a clinicopathologic study of three cases and literature review. *Diagn Pathol* 2024; 19: 1.
5. Petersson F. Nonkeratinizing nasopharyngeal carcinoma with adenomatous differentiation. *Head Neck Pathol* 2020; 14: 195-8.
6. Al Masalmeh N, Kukreja G, Zaiem F, Raza SN, Kim H, Nagasaka M, et al. p16 positive oropharyngeal small cell cancer: a case report. *Oral Oncol* 2021; 121: 105391.
7. Uhlig R, Dum D, Gorbokon N, Menz A, Büscheck F, Luebke AM, et al. Synaptophysin and chromogranin A expression analysis in human tumors. *Mol Cell Endocrinol*. 2022; 555: 111726.
8. Tomita T. Significance of chromogranin A and synaptophysin in pancreatic neuroendocrine tumors. *Bosn J Basic Med Sci* 2020; 20: 336-46.



9. Rinaldo A, Devaney KO, Ferlito A. Immunohistochemical studies in support of a diagnosis of small cell neuroendocrine carcinoma of the larynx. *Acta Otolaryngol* 2004; 124: 638-41.
10. Rooper LM, Bishop JA, Westra WH. INSM1 is a sensitive and specific marker of neuroendocrine differentiation in head and neck tumors. *Am J Surg Pathol* 2018; 42: 665-71.
11. Yuan C, Jiao F, Zhai C, Zhang J, Wang S, Zhu L. Application of INSM1 in diagnosis and grading of laryngeal neuroendocrine carcinoma. *Laryngoscope* 2021; 131: E2662-8.
12. Mukhopadhyay S, Dermawan JK, Lanigan CP, Farver CF. Insulinoma-associated protein 1 (INSM1) is a sensitive and highly specific marker of neuroendocrine differentiation in primary lung neoplasms: an immunohistochemical study of 345 cases, including 292 whole-tissue sections. *Mod Pathol* 2019; 32: 100-9.
13. Kriegsmann K, Zgorzelski C, Kazdal D, Cremer M, Muley T, Winter H, et al. Insulinoma-associated protein 1 (INSM1) in thoracic tumors is less sensitive but more specific compared with synaptophysin, chromogranin A, and CD56. *Appl Immunohistochem Mol Morphol* 2020; 28: 237-42.
14. Sakakibara R, Kobayashi M, Takahashi N, Inamura K, Ninomiya H, Wakejima R, et al. Insulinoma-associated protein 1 (INSM1) is a better marker for the diagnosis and prognosis estimation of small cell lung carcinoma than neuroendocrine phenotype markers such as chromogranin A, synaptophysin, and CD56. *Am J Surg Pathol* 2020; 44: 757-64.
15. Rocha R, Henrique R. Insulinoma-associated protein 1 (INSM1): diagnostic, prognostic, and therapeutic use in small cell lung cancer. *J Mol Pathol* 2022; 3: 140-69.
16. Rooper LM, Sharma R, Li QK, Illei PB, Westra WH. INSM1 demonstrates superior performance to the individual and combined use of synaptophysin, chromogranin, and CD56 for diagnosing neuroendocrine tumors of the thoracic cavity. *Am J Surg Pathol* 2017; 41: 1561-9.
17. Kim IE Jr, Amin A, Wang LJ, Cheng L, Perrino CM. Insulinoma-associated protein 1 (INSM1) expression in small cell neuroendocrine carcinoma of the urinary tract. *Appl Immunohistochem Mol Morphol* 2020; 28: 687-93.
18. Lewis JS, Chernock RD, Bishop JA. Squamous and neuroendocrine specific immunohistochemical markers in head and neck squamous cell carcinoma: a tissue microarray study. *Head Neck Pathol* 2018; 12: 62-70.
19. Zhao Y, Qiu Z, Ye S. Identifying immune cell infiltration and diagnostic biomarkers for nasopharyngeal carcinoma through bioinformatic analysis. *Res Square* 2024. DOI: <https://doi.org/10.21203/rs.3.rs-3816483/v1>
20. Daniel WW, Cross CL. *Biostatistics: a foundation for analysis in the health sciences*. 10th ed. Hoboken, NJ: Wiley; 2013.
21. Möller K, Gorbokon N, Hube-Magg C, Fraune C, Lennartz M, Blessin NC, et al. Comparison of INSM1 immunostaining with established neuroendocrine markers synaptophysin and chromogranin A in over 14,000 neuroendocrine and non-neuroendocrine tumors. *Am J Clin Pathol* 2023; 160 (Suppl 1): S36-7.
22. Hajra S, Kumar A, Sundriyal D, Chandra H, Balasubramanian P. A rare case report of nasopharyngeal carcinoma with multi-organ metastasis, clinico-radiologically mimicking lymphoma. *Hematol Transfus Cell Ther* 2024; 46 (Suppl 6): S389-S92.
23. Hwang TZ, Jin YT, Tsai ST. EBER in situ hybridization differentiates carcinomas originating from the sinonasal region and the nasopharynx. *Anticancer Res* 1998; 18: 4581-4.
24. Muroso S, Yoshizaki T, Tanaka S, Takeshita H, Park C, Furukawa M. Detection of Epstein-Barr virus in nasopharyngeal carcinoma by in situ hybridization and polymerase chain reaction. *Laryngoscope* 1997; 107: 523-6.